



Review on Lumpy Skin Disease Virus Characteristics and its Diagnosis in Cattle

Samson Terefe Kassa

Addis Ababa University College of Veterinary Medicine and Agriculture P. O. Box 34, Bishoftu, Ethiopia

Email: terefe.samson@yahoo.com

Article History

Received: 1 April, 2023

Revised: 10 June, 2023

Accepted: 9 July, 2023

Published: 17 July, 2023

Copyright © 2023 ARPG
& Author

This work is licensed
under the Creative
Commons Attribution
International



**BY: Creative Commons
Attribution License 4.0**

Abstract

Lumpy skin disease is characterized by its signs including eruptive, infectious and occasionally causing death to affected animals. It is caused by the family *Poxviridae* and genus *Capripox* with a strain of Neethling virus, a double stranded DNA virus. LSD clinical signs are mainly observed on skin as nodules (0.5 to 5 cm in diameter) throughout the skin surface or subcutaneous tissue involving superficial lymph nodes. Diagnosis of CaPV is based upon clinical signs with laboratory confirmation by virus isolation, polymerase chain reaction (PCR) and electron microscopy. Field diagnosis of LSD is often based on characteristic clinical signs of the disease. However, mild and subclinical forms require rapid and reliable laboratory testing to confirm diagnosis. Isolation of virus can be made from collected biopsy or at post-mortem from skin nodules, lung lesions or lymph nodes within the first week of the occurrence of clinical signs, before the development of neutralizing antibodies. There are different methods to detect LSD virus antibody from blood samples. These are serum neutralization test (SNT), indirect fluorescent antibody test (IFAT) and enzyme-linked immune-sorbent assay. LSD as a member of CaPVs, it has a single serotype, do not cause persistent infection, have a limited host range and vaccines are available that may provide long term immunity. These attributes increase the prospect of successfully implementing regional control programs, leading to the elimination of the virus and conceivably global eradication.

Keywords: Characteristics; Diagnostic options; Lumpy skin disease virus.

1. Introduction

LSD is an acute, sub-acute or in apparent viral disease of cattle, characterized by fever, lacrimation and the sudden appearance of firm circumscribed skin nodules which undergo necrosis. Similar lesions may be present in the skeletal muscles and the mucosa of the digestive and respiratory tracts. LSD is caused by LSD virus which is a member of Capri pox viruses (CaPVs) that are large double-stranded DNA viruses belonging to the family *Poxviridae*. The genus includes Sheep pox virus (SPPV), Goat pox virus (GTPV) and Lumpy skin disease virus (LSDV) [1, 2]. These viruses have genome of approximately 150 kb and share a high degree of sequence homology, with 97% identity between LSDV and both GTPV and SPPV genomes [3]. Animals affected by capripox viruses (CaPVs) will eventually clear the infection and do not become carriers [4].

The most common clinical symptoms are nodular lesions on the surface of the skin and mucous membranes. Skin nodule lesions often appear on the outside of infected cattle, such as head, neck, back, perineum, breast, and other areas of the cattle [5]. The affected cattle have varying degrees of edema and lameness in their legs [6]. *In vivo*, they often present with mucosal ulcerations high fever and enlarged lymph nodes. It is often manifested as mucopurulent nasal discharge [7, 8]. But this is not the characteristic clinical symptom of LSD. Although a large majority of the affected cattle could recover after a long period of illness, they will have long-term symptoms of mastitis, pneumonia, and deep holes in the hide [9].

Lumpy skin disease (LSD) is characterized by its signs including eruptive, infectious and occasionally causing death to affected animals [10]. It is caused by the family *Poxviridae* and genus *Capripox* with a strain of Neethling virus, a double stranded DNA virus [11]. LSD is considered as list A disease by OIE considering its huge impact on socio-economic status of the community. The economic implication of this disease on cattle industry usually related to debilitating chronic impacts on animal that causes production problems. These problems include reduction in milk production, abortion, temporary or permanent sterility and damaged hides [10, 12].

LSD presents itself in different forms including acute, sub-acute or in apparent diseases in which their severity is dependent on the virus strain and susceptible breed. As mentioned by Radostits, *et al.* [13], *Bos indicus* is known to be less susceptible to clinical disease than *Bos taurus*. Furthermore, Carn and Kitching [14] identified that even lactation status of a cow influence the severity of this disease and showed cows in lactation are more at risk. LSD is less contagious with low mortality (less than 10% in most reports) and varying morbidity rate (1-90% mostly and

few reports of 100%) [15, 16]. Apart from factors related to animals, environmental factors such as season can have its own impact on LSD occurrence. As such, LSD case is expected to be high in wet than dry seasons which is related to a favourable condition of biting insects that taught to transmit the disease [17].

The diagnosis of *Capripox* virus (CaPVs) diseases can be attained with clinical signs that proceed with a confirmation of laboratory; i.e. virological and/or serological methods. One of the major problems encountered in the CaPVs diagnosis is poor level of sero-conversion. For this reason, the confirmation of the disease is generally based on the detection of *capripox* virions or antigens through electron microscopy, virus isolation and Real-time PCR [18]. The poor sero-conversion is expected to relate with the predominance of cell mediated immune response during CaPVs infection. Yet, the humoral immunity can also play its own role in fighting the antigen. The later types of immunity present serum antibody titration which can reflect the protection level of the individual animal. This mechanism of humoral immunity is used in the blood test for LSDV antibody detection [19]. Moreover, the lack of available diagnostic kits for cellular immune response to monitor vaccine efficacy made a higher preference to humoral immune response detection to monitor vaccine efficacy [20].

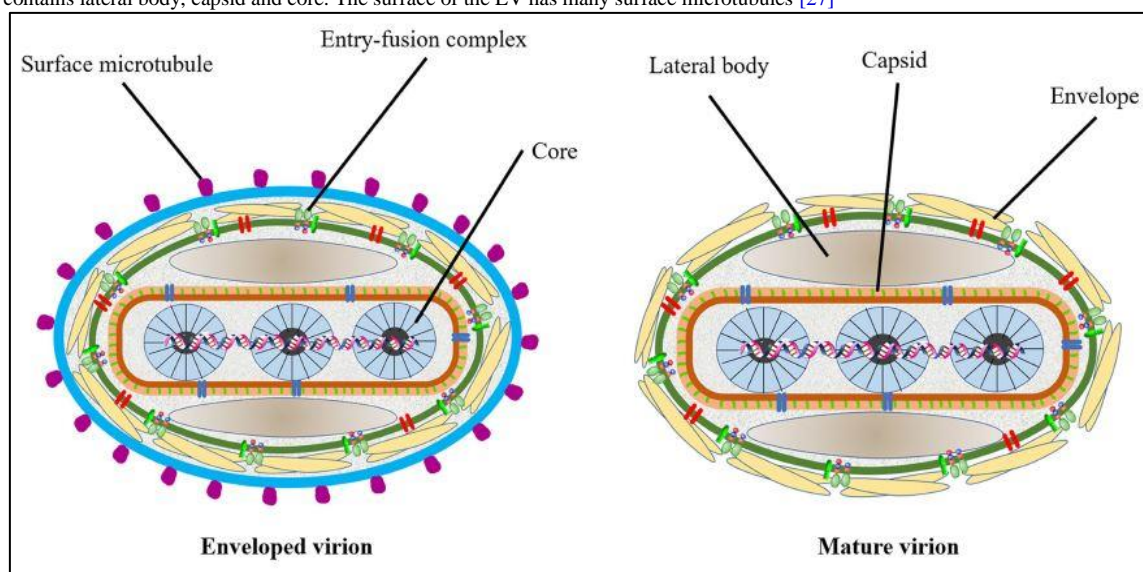
There are different methods to detect LSD virus antibody from blood samples. These are serum neutralization test (SNT), indirect fluorescent antibody test (IFAT) and enzyme-linked immune-sorbent assay (ELISA) [18, 21]. From these tests, SNT are considered to be a reference and the unique validated serological test that has been used to evaluate immune status in individual animals or in post-vaccinated populations. It was also mentioned in OIE [18] that, SNT is the only serological test validated by the OIE with a high specificity for detecting *Capripox* virus-specific antibodies. This is mostly due to its strong specificity that can reach 100% but less sensitivity between 70% and 96% for CaPVs. However, coupling with the use of standard viral strain and pre-vaccination antibodies control can improve this less sensitivity of the test [19].

2. Lumpy Skin Disease Virus Characteristics

Lumpy skin disease is caused by Lumpy skin disease virus, one of the members of Capri pox viruses which are enveloped, brick shaped with complex symmetry, measuring 300x270x200 nm in size [22]. Mature *Capripoxvirions* have a more oval profile and larger lateral bodies than *Orthopoxvirions* [23]. These viruses are generally resistant to drying, survive freezing and thawing, and remain viable for months in the lyophilized state. Sensitivity to heat differs among strains. CaPVs are double-stranded DNA viruses with genomes approximately 150 kbp in size. LSDV shares a close genetic relationship with SPPV and GTPV [24] but has an additional nine genes that are non-functional in SPP and GTP viruses, some of which are likely responsible for their ability to infect cattle. CaPV isolates are extremely conserved with genome identities of at least 96% between SPPV, GTPV and LSDV [3, 16].

LSDV genome consists of a central coding region which is bounded by identical 2.4 kbp-inverted terminal repeats and contains 156 putative genes. LSDV genes share a high degree of colinearity and amino acid identity (average of 65%) of its genomic region with genes of other known mammalian poxviruses like suipoxvirus, yatapoxvirus, and leporipoxviruses [25]. Even if CaPVs share high nucleotide sequence identity, they are phylogenetically distinct. Phylogenetic analysis showed that members of the genus could be delineated into three distinct clusters of GTPV, SPPV and LSDV based on the P32 genomic sequence. There is an additional aspartic acid at 55th position of P32 present in sheep poxvirus which is absent in GTP and LSD viruses [26].

Figure-1. The prediction diagram of LSDV structure mode. Mature virion of LSDV (MV), sometimes mature virion is surrounded by a lipid membrane derived from the endoplasmic reticulum (EV). The surface of the virus is envelope, which contains some entry-fusion complex. The virus contains lateral body, capsid and core. The surface of the EV has many surface microtubules [27]



2.1. Viral Genome

LSDV is a double stranded DNA virus. The size of the LSDV genome is 151 kbp and it consists of a central coding region with identical 2.4 kbp inverted terminal repeats and 156 putative genes. The genes encoding host range, virulence and immune evasions are located at the terminal parts of the genome [3].

2.2. Replication Cycle

The replication of LSDV occurs in the cytoplasm of the host cell in intracytoplasmic eosinophilic inclusion bodies which can be detected using microscopic examination of a haematoxylin and eosin-stained LSDV infected monolayer of cells [27].

2.3. Physico-Chemical Property

LSDV is remarkably stable for long periods at ambient temperature, especially in dried scabs. It can persist in necrotic skin nodules for up to 33 days or longer, desiccated crusts for up to 35 days, and at least 18 days in air-dried hides. It can remain viable for long periods in the environment. The virus is vulnerable to sunlight and detergents containing lipid solvents, but in dark environmental conditions, such as contaminated animal sheds, it can persist for several months. The virus can be inactivated at temperature of 55°C for 2 hours and 65°C for 30 minutes. In contrast it can be recovered from skin nodules kept at -80°C for 10 years and infected tissue culture fluid stored at 4°C for 6 months. It is susceptible to highly alkaline or acid pH but, no significant reduction in titer when held at pH 6.6-8.6 for 5 days at 37°C. The virus is susceptible to ether (20%), chloroform, formalin (1%), phenol (2% for 15 minutes), sodium hypochlorite (2-3%), iodine compounds (1:33 dilution) and quaternary ammonium compounds (0.5%) [28]. The virus is susceptible to highly alkaline or acid pH. LSDV is very resistant to inactivation. Meanwhile, the virus is susceptible to sunlight and detergents containing lipid solvents, while, in dark environmental conditions, such as contaminated animal sheds, it can persist for many months [29].

2.4. Lumpy Skin Disease Virus with Other Capripox Viruses

Capripoxviruses comprise 1 of 8 genera within the subfamily Chordopoxvirinae, family Poxviridae. Members of the genus are sheeppox, goatpox, and lumpy skin disease viruses that cause disease in sheep, goats, and cattle respectively. Lumpy skin disease virus (LSDV) is endemic in Africa, whereas goatpox and sheeppox are endemic in Africa, the Middle East, and Asia and are the most economically significant pox diseases of ruminants. CaPVs are double-stranded DNA viruses with genomes approximately 150 kbp in size. Goat and SPP share at least 147 putative genes. LSDV has an additional 9 genes likely involved in the ability to infect cattle. DNA analysis using restriction endonucleases on field samples and vaccine strains showed 80 % homology between strains of CaPVs. CaPVs are enveloped or non-enveloped, brick or oval shaped viruses with similar morphology (except parapoxviruses). CaPV virions are different than orthopox virus virions in that they have a more oval profile, as well as larger lateral bodies. The average size of CaPVs is 320 nm by 260 nm [30].

It is not possible to distinguish between different strains of CaPV using serological assays [30]. Molecular studies have demonstrated that LSDV, SPPV and GTPV are phylogenetically distinct [3, 31] and, recently, by sequencing the host specific Gprotein coupled chemokine receptor (GPCR), or RNA polymerase (RPO30) genes, species specific molecular assays have been developed for differentiation of CaPVs, enabling the phylogenetic grouping of CaPVs [32-34]. Gelaye, *et al.* [24] developed a new molecular assay for CaPV genotyping using unlabelled snapback primers in the presence of dsDNA intercalating dye. This assay is able to simultaneously detect and genotype CaPVs.

3. Epidemiology

Lumpy skin disease (LSD) which was occurred as new skin disease, referred as pseudo urticaria", of cattle was first reported in 1929 in Northern Rhodesia (now Zambia) from where the disease spreads to other southern African countries by the 1940s [23]. In Ethiopia, LSD was first reported in 1981 in the northwestern part of the country near lake Tana [35, 36]. Capri poxvirus infections are generally host specific and not reported on CaPV infecting all three species: sheep, goats and cattle [37, 38]. They have also specific geographic distributions in which diseases of goat pox and sheep pox are prevalent in Africa above the equator, Asia, the Middle East, and occasional outbreaks occur in regions of Europe surrounding the Middle East. In contrast, LSD is endemic in Africa and outbreaks have been occurred in the Middle East countries surrounding Egypt and in some parts of Europe like Greece [16, 39, 40].

Lumpy skin disease is one of the economically significant diseases in Africa and the Middle East countries that cause severe production loss in cattle. The world organization for animal health (OIE) categorizes the disease as notifiable diseases because of its severe economic losses. The economic importance of the disease was mainly due to having high morbidity rate rather than mortality. The financial implication of these losses is greatly significant to the herd owners, consumers and the industrial sectors which can process the livestock products and by products. In intensive farming of cattle, the direct and indirect production losses caused by LSD were estimated to be as high as 45-60%. It was reflected that the severity of the disease was much more in developing countries where the poorest small scale farmers was found [36].

The disease was mainly affects cattle with subsequent effects on production through the morbidity and reduced productivity [41]. Major consequences of the disease are retarded genetic improvement, limits the ability of the animal to work, draught power and traction loss, abortion in pregnant cows, marked reduction of milk yield during the active case of the disease, sterility and infertility in both sexes of cattle, permanent damage to hide and chronic debility in beef cattle [10, 42].

The morbidity and mortality rates for LSD vary greatly in different endemic areas depending on the severity of strain, prevalence of insect vectors and susceptibility of the host [43]. An outbreak in a previously free country could be expected to result in a high morbidity rate. If LSD became endemic, continuing economic loss and poor productivity would occur due to stock losses, reduced production in cattle industries and cost of preventative

vaccination. Permanent loss of some markets would also be expected, with associated downturn in rural economy and increased rural unemployment [36].

Infected cattle are the main source of LSDV infection. Transmission of LSD among cattle is inefficient, and arthropod-vector transmission may be significant in epizootic outbreaks and in the spread of LSD into non enzootic regions and direct contact could be a minor source of infection [44]. LSDV can be found in cutaneous lesions, saliva, respiratory secretions, milk and semen. Shedding in semen may be prolonged; viral DNA has been found in the semen of some bulls for at least 5 months after infection. The most likely way for LSD to enter a new area is by introduction of infected animals. Extensive livestock production system allows maximum chance for different herd mixing during utilization of communal grazing lands and watering points. Under this prevailing system it is likely to speculate that the introduction and spread of LSD infection could have favorable environment. Uncontrolled cattle movements due to trade, pastoralism, vector insects' population and dynamic, wet climate which favor insect multiplications and other reasons of cattle movement from place to place could render potential risk factors for the transmission of the disease from herd to herd and from place to place. Animals can be infected experimentally by inoculation with material from cutaneous nodules or blood, or by ingestion of feed and water contaminated with saliva. LSDV has been proven to be transmissible to calves through infected milk [45].

Biting insects including flies (*Stomoxys* and *Tabanus*) and mosquito (*Culex* and *aedes*), are mechanical vectors and the major means of LSD virus transmission. And also LSD virus has been isolated from *Stomoxys calcitrans* and *Musca confisicata* and transmitted experimentally using *Stomoxys calcitrans* but other vectors are also suspect including *Biomyia*, *Culicoides*, *Glossina* and *Musca* species. However, in a recent study, despite the detection of virus in mosquitoes (*Anopheles stephensi*, *Culex quinquefascuatus*) the stable fly and a biting midge (*Culicoides nebeculosis*) after they had fed on cattle with lumpy skin disease, the infection did not transmit to susceptible cattle when these arthropods were allowed to re-feed on them [46]. In a recent study researchers found molecular evidence suggesting that LSD can be transmitted through hard (Ixodid) ticks (*Rhipicephalus decoloratus*, *Rhipicephalus appendiculatus* and *Amblyomma hebraeum*) [36].

4. Pathogenesis

LSD is caused by infectious LSDV and accompanied with febrile reaction [45]. The disease affects cattle and tends to be more severe in milking cows in the peak of lactation and in young animals [47]. LSDV replicates inside the host cells such as macrophages, fibroblasts, pericytes and endothelial cell in the lymphatics and blood vessels walls lead to developing vasculitis and lymphangitis, while thrombosis and infarction may develop in severe cases. Mechanism by which the virus observed to cause skin lesions is through to replication of the virus in specific cells such as pericytes and endothelial cells of lymphatic and blood vessel walls. Histopathological sections of early skin lesions of epidermis show an epitheloid cells, lymphocytes, macrophages, plasma cells and fibroblast proliferation appear in later stages and if secondary infection occurs, necrosis, polymorph nuclear and red cells seen. Typical eosinophilic, intracytoplasmic pox inclusion bodies may be seen in cells of epithelioid, hair follicles and cells of muscles and skin glands [48, 49].

Pathogenic mechanism of viral disease involves implantation of virus at the portal of entry, replication at that site, spread to target organs, and spread to sites of shedding of virus into the environment. Viral disease occurs if the virus replicates in essential cells sufficiently and destroys them directly or damages organ function indirectly as a result of the host immune response to the presence of virus proteins. The incubation period of LSD under field conditions is two to four weeks. Intravenous, intradermal and subcutaneous routes are used in experimental infection. A localized swelling at the site of inoculation after four to seven days and enlargement of the regional lymph nodes, develop after subcutaneous or intradermal inoculation of cattle with LSDV. However, generalized eruption of skin nodules usually occurs seven to 19 days after inoculation. Viraemia occurred after the initial febrile reaction and persisted for two weeks [45].

5. Clinical Signs

Lumpy skin disease is infectious, eruptive and occasionally fatal disease of cattle. It is an acute to chronic viral disease characterized by skin nodules in the skin and other body parts. It might be exacerbated by secondary bacterial complication [50]. In animals that develop clinical disease, there is a biphasic febrile reaction that may exceed 40°C. They remain febrile for 4 to 14 days. This is accompanied by depression, disinclination to move, in appetite, salivation, lachrymation and a nasal discharge, which may be mucoid or mucopurulent. The superficial lymph nodes, especially prescapular, precrural and subparotid, are usually markedly enlarged. The eruption of nodular skin lesions usually occurs within 48 hours of onset of the febrile reaction. Predilection sites are the skin of the head, neck, perineum, genitalia, udder and limbs. Nodules are 5 to 50 mm in diameter, circumscribed, firm, round raised, and involve the skin, subcutaneous tissue and sometimes even the underlying muscles. Some acutely affected animals may develop severe subcutaneous oedema of the ventral parts of the body such as the dewlap, brisket, limbs, udder, scrotum and vulva. Oedematous and necrotic lesions in the udder may result in mastitis. In some animals, necrotic lesions in the trachea and lungs may lead to pneumonia. Bulls usually become temporarily infertile, but sometimes because of severe orchitis they may become permanently infertile. Pregnant cows may abort and be in anoestrus for several months [12].

6. Diagnostic Options of LSD

6.1. Clinical Signs

All cattle breeds, both sexes and all ages groups are susceptible. LSDV also affect sheep and goats experimentally though natural infection is limited to cattle and Asian water Buffalo. This virus usually causes low mortality and relatively high morbidity. The course of the disease can exist in acute, subacute or chronic forms. In experimental infection, about 40% to 50% of animals develop generalised skin lesions while the rest appeared to be subclinical. In experimental infection, incubation period has been seen to be shorter (about 5 days) than that of natural infection (i.e. 2 to 4 weeks) [10].

LSD clinical signs mainly observed on skin as nodules (0.5 to 5 cm in diameter) throughout the skin surface or subcutaneous tissue involving superficial lymph nodes (mainly sub-scapular and pre-crural lymph nodes) [23]. Furthermore, the nodules spread to the nasal, oral, ocular, and genital mucosa. These cutaneous lesions may resolve rapidly or may indurate and persist as hard lumps, or become sequestered to leave deep ulcers partly filled with granulation tissue, which often suppurates [51].

Figure-2. Nodules on neck and abdominal areas



Papules most easily observed in hairless areas of perineum, udder, inner ear, muzzle and eyelids [52]. Some cattle can develop edematous swelling of legs that causes lameness. Severity of infection is more in cows at peak lactation that can reflect it through a sharp drop in milk production. This drop in milk production is usually associated with the higher fever (i.e. 40 to 41 oC) and mastitis due to secondary bacterial infection [23]. In bulls, LSD could cause infertility temporarily though severe orchitis may cause a permanent sterility. This disease also has an effect on pregnant cows by causing either abortion or anoestrus for several months. Additionally, pneumonia may be observed as a result of secondary bacterial complications of upper respiratory tract that undergoes extensive necrosis. Even after recovery of this respiratory signs, stenosis of trachea has been reported following the healing of lesions by scar formation (Center for food security and public health/[41]). Generalized clinical signs, that are unspecific to LSD, are also common. These are depression, disinclination to move, inappetence, salivation, lachrymation and a nasal discharge, which may be mucoid or muco-purulent.

6.2. Histopathology

In acute stage of LSD, histopathological changes in skin lesions showed vasculitis, perivasculitis, lymphangitis, thrombosis, oedema, necrosis and infarction. Different cells infiltrate necrotic areas in orderly manner as neutrophils, macrophages and eosinophils (sometimes) exist immediately followed by lymphoblasts, lymphocytes, plasma cells, macrophages and fibroblasts. Additionally, eosinophilic intracytoplasmic inclusion bodies are seen mainly in macrophages, endothelial cells, pericytes and keratinocytes in the skin but also occur in epithelial cells associated with the hair follicles, skin glands and in smooth muscle cells. Histo-pathological methods using haematoxylin and eosin staining of skin lesions can visualise intra-cytoplasmic inclusion bodies of LSD virus-infected cells. Another method of immunohistochemical techniques with immunoperoxidase staining is used to mark viral antigens of skin lesion [53]. Histopathology can also be considered as an important tool to exclude different causes of skin nodules. This is specially a good tool to rule out viral, bacterial or fungal causes of nodular development in clinical cases and characteristic cytopathic effects (necrotised epidermis, ballooning degeneration of squamous epithelial cells and eosinophilic intracytoplasmic inclusion bodies) in cases of LSD [54].

6.3. Electron Microscopy

LSDV can be identified using transmission electron microscopy. The characteristic poxvirus virion can be visualised using a negative staining preparation technique followed by examination with an electron microscope. Material from the original biopsy suspension is prepared for examination under the transmission electron microscope by floating a 400-mesh hexagon electron microscope grid, with pileoformcarbon substrate activated by glow

discharge in pentylamine vapour, on to a drop of the suspension placed on parafilm or a wax plate. After 1 minute, the grid is transferred to a drop of Tris/EDTA buffer, pH 7.8, for 20 seconds and then to a drop of 1% phosphotungstic acid, pH 7.2, for 10 seconds. The grid is drained using filter paper, air-dried and placed in the electron microscope. The capripox virion is brick shaped, covered in short tubular elements and measures approximately 290×270 nm. A host-cell-derived membrane may surround some of the virions, and as many as possible should be examined to confirm their appearance [10].

6.4. LSD Virus isolation

Viral isolation and identification are methods of confirming LSDV. For isolation, primary or secondary pre-pubertal lamb testis cell cultures are most commonly used for this virus. Because these cell cultures are more sensitive than kidney, muscle, lung, skin, thymus or endothelial cells. In the culture, virus shows a characteristic features that can be used to differentiate LSDV from that of herpes virus that causes pseudo-LSD. This differentiating method is achieved through a staining of cultures infected with suspensions of early skin lesions between 48 to 56 hrs. The resulting characteristic feature of cytopathic effect coupled with intra-cytoplasmic location of inclusion bodies is used to identify LSDV from herpes virus. The cytopathic effects resulting from the LSDV develop at 5 to 14 days in most primary cultures, but it is recommended if they have to be frozen and thawed with a possibility of one blind passage to be carried out. This process will detect LSDV strains that adapt slowly to the cultures or that were present only in very small amounts in the original sample [55].

LSD virus can grow in tissue culture of bovine, ovine or caprine origin, although primary or secondary culture of bovine dermis cells or lamb testis (LT) cells are considered to be the most susceptible, particularly those derived from a breed of wool sheep. Infected cells develop a characteristic CPE consisting of retraction of the cell membrane from surrounding cells, and eventually rounding of cells and margination of the nuclear chromatin. At first only small areas of CPE can be seen, sometimes as soon as 2 days after infection; over the following 4–6 days these expand to involve the whole cell sheet. If no CPE is apparent by day 14, the culture should be freeze–thawed three times, and clarified supernatant inoculated on to fresh LT culture [10].

Although CPV will grow in a variety of cell types from cattle, goat, and sheep origin; primary lamb kidney or primary lamb testis are the most commonly used cell systems for isolation. Use of these cells is preferred mainly because of their ability to support the replication of a variety of CPV isolates; and the ability to obtain sufficient numbers of cells from the respective organs. Weiss in 1968 used primary lamb testes (LT) to grow CPV. However, the reduced availability of lambs, mainly owing to efforts to minimize animal use, has necessitated investigating the suitability of continuous cell lines [56].

Different studies are conducted on the search to find continuous cell lines suitable for the primary isolation of the CPV. The utility of OA3.Ts cells for CPV propagation, titration, and serological detection while comparing with primary lamb kidney (LK) cell was evaluated. The study found that OA3.Ts cells are a suitable ovine cell line for the propagation of CPV (both laboratory strains as well as field isolates). Unlike other primary and secondary ovine cells, the OA3.Ts cells provide reproducible virus growth and are susceptible to infection by a variety of CPV strains, without culture adaptation. Other continuous cell lines, vero, ESH-L, Madin-Darby bovine kidney (MDBK) are also used for isolation of LSDV [57].

6.5. Molecular Detection Methods

LSDV is possibly confirmed with molecular methods and transmission electron microscope. From molecular techniques both real-time and conventional polymerase chain reaction (PCR) through genome detection with primers specific to *capripox* virus from different samples including blood, tissue biopsy, tissue culture and semen [18, 23]. However, this method has its own limitation in differentiating between the strains of *Capripoxvirus* (LSDV, SPV and GPV). Tulman, *et al.* [3], justify this with the genome similarity between LSDV, GPV and SPV that ranges from 96% between viral species to 99% between isolates of the same species. Nevertheless, the use of primers for viral attachment protein gene and the viral fusion protein gene is specific for all the strains within the genus *Capripoxvirus*. Moreover, Bowden, *et al.* [58] stated the valid use of probe in real-time PCR method using primers for *Capripoxvirus* detection. On the other hand, molecular tests using loop-mediated isothermal amplification to detect *Capripoxvirus* genomes are also reported as a simple and cost effective method with a comparable sensitivity and specificity with real-time PCR [59].

6.6. Serological Tests

All the viruses in the *Capripoxvirus* genus share a common major antigen for neutralising antibodies and it is thus not possible to distinguish strains of capripoxvirus from cattle, sheep or goats using serological techniques. Virus neutralization, Agar gel immunodiffusion, Indirect fluorescent antibody test are sensitive serological diagnostic system for the detection of antibody to *Capripoxvirus* structural proteins [10]. Though immune response against *capripoxvirus* depends mainly on cell-mediated response, humoral immunity also plays its own important role in curing circulating antigen. This circulating antibody from humoral immunity remains mostly for seven to eight months. However, immunity of newborn captured from dam provides protection for at least six months [10, 60].

Serological tests are unable to distinguish LSDV, SPV and GPV because they share a common major antigen for neutralising antibodies [10]. Even in the existing tests, interpretations are not easy as a result of lower antibody titre in animals mildly affected and the one that are vaccinated [15]. Furthermore, Tuppurainen and Oora [12] stated the difficulty of serological assay that emanates from the nature of virions surface proteins. This is mainly due to the

formation of different antibodies in the host for different surface proteins of non-enveloped and enveloped intracellular as well as extracellular virions. So, their antibodies proportion varied during the different stages of infection caused by the different virions [12]. There are different serological techniques to detect LSDV antibodies; these serological tests include indirect fluorescent antibody test (IFAT) that used to determine LSD sero-prevalence [21, 61], ELISA virus neutralization test (VNT), and immune-peroxidase monolayer assay (IPMA) [62].

6.6.1. Indirect Fluorescent Antibody Test (IFAT)

IFAT is a method of detecting antibody against LSD. The timeline for antibodies to be detected mostly start from two days after the onset of clinical signs and reach at rise between twenty one and 42 days though the antibody continue to exist till seven months [10]. The method of IFAT uses fluorescein isothiocyanate conjugated anti-bovine gamma-globuline (IgG) of rabbit diluted in lamb serum as a blocking buffer [21]. The end result is checked with Zeiss Fluorescent microscope under 40 x magnifications. In this observation, bright fluorescence foci showing the reaction between antibody and virus is seen as a positive test serum while dark field or dim gray foci in the absence of specific antibodies in the serum [21, 61, 63]. Though IFAT is used commonly due its good sensitivity, the test has limitation as it does not differentiate if antibodies of rarely occurring Parapox and Orthopox virus which affect its specificity at low serum dilution rates.

6.6.2. Enzyme Linked Immune-Sorbent Assay (ELISA)

Previously ELISA that mostly relies on recombinant CaPV proteins was developed. This ELISA used either mature virion envelope protein P32 or viral core protein 095 and 103 as coating antigen [58]. Additionally, there is a difficulty to get sufficient quantities of heat inactivated antigen and instability of recombinant antigens [58]. However, this method of ELISA lacks sufficient sensitivity to be used specially for larger scale [64].

In recent times, commercially available ELISA (manufactured by IDVet) that is possibly used in both infected and vaccinated animals to detect antibodies [65]. The one used by Ochwo, *et al.* [65] was ID Screen® Capripox double antigen multi-species ELISA and able to detect antibodies against *Capripox* viruses including LSDV, SPV and GPV. This ELISA has very high specificity (> 99.7%) and unable to cross-react with parapox viruses. Another important feature of this ELISA is its easiness to perform and allows for high throughput screening without requiring high-level containment facilities [64].

6.6.3. Immunoperoxidase Monolayer Assay (IPMA)

The development of IPMA is commonly used for different diseases including swine influenza [66], swine hepatitis E [67], porcine circovirus type 2 (PCV2) [68], and African swine fever [69]. This test is advantageous in its simplicity to perform, basic equipment requirements and the need for small amounts of purified antigen without affecting its sensitivity and specificity [68]. Recently, Haegemana, *et al.* [53] used IPMA for the detection of LSD antibodies.

6.6.4. Virus Neutralization Test (VNT),

In most cases serum (SNT) and virus (VNT) neutralisation test are used interchangeably. But it has minor differences in the use of a either known antigen (SNT) or antibody (VNT). During natural infection, animals that develop a neutralising antibody have a different titre at different time period. Accordingly, increment in antibody titre is expected in approximately one week after the onset of fever. The antibody continues to rise and reach its peak between two to three weeks. However, the titre starts to fall down after three weeks and become below detectable level during neutralisation [70].

The use of SNT as a serological method to detect antibody titre is very common regardless of the lengthy and tedious procedure. This method is the only validated test for detecting specific antibodies to *Capripoxviruses*. With regard to antibody testing in *Capripoxviruses*, it is most commonly and widely used antibody testing method [16, 71]. However, this test cannot distinguish antibodies of different strains of *Capripoxviruses* (LSDV, SPV and GPV) as they share a common major antigen for neutralizing antibodies [10]. In spite of this, SNT has a strong specificity (more than 97%) though sensitivity (70 to 96%) is relatively less [21, 63]. Nevertheless, coupling with a reference antibody level before exposure of animal can be used for comparison and there by improves the less sensitivity of SNT [19].

6.7. Differential Diagnosis

Different skin lesions from pseudo lumpy skin disease (caused by bovine herpesvirus-2), insect bites, demodex infection, onchocercosis, besnoitiosis and dermatophilosis can mistakenly suspected as LSD. Additionally, diseases that cause lesions on mucosa like rinderpest, bovine viral diarrhoea/mucosal disease, foot and mouth disease and bovine malignant catarrhal fever can still confuse with LSD. The way to differentiate those diseases from LSD varied depending on the clinical signs and in some laboratory diagnosis might be an important tool for confirmation. In pseudo-LSD, their clinical signs are milder with a characterized superficial nodule, which might only confuse early stage of LSD. Further laboratory techniques with observation of intra-nuclear inclusion bodies and viral syncytia in histo-pathological examination characterise bovine herpesvirus-2 as it is absent in LSD. For the rest of the diseases, assessing their clinical signs coupled with epidemiological evidence can play a greater role in identifying one from the other [18].

7. Conclusion and Recommendations

Lumpy skin disease (LSD) is a generalized skin disease which is an infectious, eruptive, occasionally fatal disease of cattle caused by a virus associated with the Neethling poxvirus in the genus Capri poxvirus of the family *Poxviridae*. Lumpy skin disease is caused by lumpy skin disease virus (LSDV), which can induce cattle with high fever and extensive nodules on the mucosa or the scarfskin, seriously influencing the cattle industry development and international import and export trade. The nodules are firm, and may extend to the underlying subcutis and muscle. Acute histological key lesions consist of epidermal vacuolar changes with intracytoplasmic inclusion bodies and dermal vasculitis. Chronic key histological lesions consist of fibrosis and necrotic sequestrum. Various strains of capripoxvirus are responsible for the disease. These are antigenically indistinguishable from strains causing sheep pox and goat pox yet distinct at the genetic level. Different diagnostic techniques are available for early detection of the disease. Laboratory confirmation of LSD is most rapid using a real-time or conventional polymerase chain reaction (PCR) method specific for capripoxviruses in combination with a clinical history of a generalised nodular skin disease and enlarged superficial lymph nodes in cattle. Based on the above conclusion the following recommendations are forwarded.

- Broader and detailed investigation including sequence characterization and determination of their evolutionary relationship of the viruses as compared to the vaccine strain in use
- Suitable cell lines for fast isolation of the virus need to be identified.
- Study on the genetic similarity/difference among the vaccine strain with the field isolates should be continuing.
- Pathogenicity and immunological study is necessary to know more about the disease
- Cellular immune response against LSD need to be assessed to understand the full aspects of immune response and correlate it with vaccine protection

References

- [1] Facquet, C. M., 2005. *Virus taxonomy: Viiiith report of the international committee on taxonomy of viruses*. Academic Press.
- [2] Murphy, F. A., 2012. *Virus taxonomy: classification and nomenclature of viruses*. 10 ed. Springer Science and Business Media.
- [3] Tulman, E. R., Afonso, C. L., Lu, Z., Zsak, L., Kutish, G. F., and Rock, D. L., 2001. "Genome of lumpy skin disease virus." *Journal of Virology*, vol. 75, pp. 7122-7130.
- [4] Gari, G., Abie, G., Gizew, D., Wubete, A., Kidane, M., Asgedom, H., Bayissa, B., Ayelet, G., Ourae, C. A., et al., 2015. "Evaluation of the safety, immunogenicity and efficacy of three Capri poxvirus vaccine strains against lumpy skin disease virus." *Vaccine*, vol. 33, pp. 3256-3261.
- [5] Molla, W., Frankena, K., Gari, G., and de Jong, M. C. M., 2017. "Field study on the use of vaccination to control the occurrence of lumpy skin disease in Ethiopian cattle." *Prev. Vet. Med.*, vol. 147, pp. 34-41.
- [6] Salib, F. A. and Osman, A. H., 2011. "Incidence of lumpy skin disease among Egyptian cattle in Giza Governorate, Egypt." *Veterinary World*, vol. 4, p. 4.
- [7] Lubinga, J. C., Tuppurainen, E. S., Mahlare, R., Coetzer, J. A., Stoltsz, W. H., and Venter, E. H., 2015. "Evidence of transstadial and mechanical transmission of lumpy skin disease virus by *Amblyomma hebraeum* ticks." *Transbound. Emerg. Dis.*, vol. 62, pp. 174–182.
- [8] Elhaig, M. M., Selim, A., and Mahmoud, M., 2017. "Lumpy skin disease in cattle: frequency of occurrence in a dairy farm and a preliminary assessment of its possible impact on Egyptian buffaloes." *Onderstepoort J. Vet. Res.*, vol. 84, pp. e1–e6.
- [9] Selim, A., Manaa, E., and Khater, H., 2021a. "Molecular characterization and phylogenetic analysis of lumpy skin disease in Egypt." *Comp. Immunol. Microbiol. Infect. Dis.*, vol. 79, p. 101699.
- [10] OIE, 2010. *Lumpy skin disease; manual of diagnostic tests and vaccines for terrestrial animals*. Paris: World Organization for Cattle Health. pp. 1-13.
- [11] King, A. M. Q., Adams, M. J., Carstens, E. B., and Lefkowitz, E. J., 2012. *Virus taxonomy: Classification and nomenclature of viruses: 9th report of the international committee on taxonomy of viruses*. Waltham London: Academic Press.
- [12] Tuppurainen and Oura, C. A. L., 2012. "Review: Lumpy skin disease: An emerging threat to Europe, Middle East and Asia." *Trans. Emerg. Dis.*, vol. 59, pp. 40-48.
- [13] Radostits, O. M., Gay, C. C., Hinchcliff, K. W., and Constable, P. D., 2007. *Veterinary Medicine: A textbook of diseases of cattle, horses, sheep, pigs and goat*. 10th ed. Philadelphia, USA.: WB Saunders Co., pp. 1424-1426.
- [14] Carn, V. M. and Kitching, R. P., 1995. "The clinical response of cattle experimentally infected with lumpy skin disease (Neethling) virus." *Archives of Virology*, vol. 140, pp. 503–513. Available: <https://doi.org/10.1007/BF01718427>
- [15] Coetzer, J. A. W., 2004. *Lumpy skin disease*. In: *Infectious diseases of livestock*. Coetzer J.A.W. And Justin .C. (eds). 2nd ed. Cape Town, South Africa: Oxford University Press. pp. 1268-1276.
- [16] Babuik, S., Bowden, T. R., Boyle, D. B., Wallace, D. B., and Kitching, R. P., 2008. "Capripox viruses: An emerging worldwide threat to sheep, goats and cattle." *Transboundary and Emerging Diseases*, vol. 55, pp. 263-272.
- [17] Gari, G., Waret-Szkuta, A., Grosbois, V., Jacquiet, P., and Roger, F., 2010. "Risk factors associated with observed clinical lumpy skin disease in Ethiopia." *Epidemiol Infect.*, vol. 136, pp. 1657-1666.

- [18] OIE, 2017. *Manual of diagnostic tests and vaccines for terrestrial animals. In: Chapter 2.4.13. Lumpy Skin Disease.*
- [19] Bhanuprakash, V., Indrani, B. K., Hosamani, M., and Singh, R. K., 2006. "The current status of sheep pox disease." *Comp. Immunol. Microbiol. Infect. Dis.*, vol. 29, pp. 27–60.
- [20] Tuppurainen, E. S. M., Venter, E. H., Shisler, J. L., Gari, G., Mekonnen, G. A., Juleff, N., Lyons, N. A., De Clercq, K., Upton, C., *et al.*, 2017a. "Review: Capripoxvirus diseases: Current status and opportunities for control." *Transbound Emerg Dis.*, vol. 64, pp. 729-745.
- [21] Gari, G., Biteau-Coroller, F., LeGoff, C., Caufour, P., and Roger, F., 2008. "Evaluation of indirect fluorescent antibody test (IFAT) for the diagnosis and screening of lumpy skin disease using Bayesian method." *Vet. micr.*, vol. 129, pp. 269-80.
- [22] Shakya, S., 2001. *Identification and molecular characterization of immunogenic proteins of capripox virus.* Uj'taranchal, India: G. B. Pant University of Agriculture and Technology Pantnagar - 263145, (U.S.Nagar).
- [23] Abdulqa, H. Y., Rahman, H. S., Dyary, H. O., and Othman, H. H., 2016. "Lumpy skin disease. Reproductive immunology." *Open Access*, vol. 1, pp. 1-6.
- [24] Gelaye, E., Belay, A., Ayelet, G., Jenberie, S., Yami, M., Loitsch, A., Tuppurainen, E., Grabherr, R., Diallo, A., *et al.*, 2015. "Capripox disease in Ethiopia: Genetic differences between field isolates and vaccine strain, and implications for vaccination failure." *Antiviral Research*, vol. 119, pp. 28-35.
- [25] Madhavan, A., Venkatesan, G., and Kumar, A., 2016. "Capripoxviruses of small ruminants: Current updates and future perspectives." *Asian Journal of Animal and Veterinary Advances*, vol. 11, pp. 757-770.
- [26] Hosamani, M., Mondal, B., Tembhurne, P. A., Bandyopadhyay, S. K., Singh, R. K., and Rasool, T. J., 2004. "Differentiation of sheep pox and goat poxviruses by sequence analysis and PCR-RFLP of p32 gene." *Virus Genes*, vol. 29, pp. 73-80.
- [27] Liang, Yao, K., Wang, S., Yin, J., Ma, X., Yin, Wang, X., and Sun, Y., 2022. "Understanding the research advances on lumpy skin disease: A comprehensive literature review of experimental evidence." *Front. Microbiol.*, vol. 13, p. 1065894.
- [28] OIE, 2013. *World organization for animal health. Lumpy skin disease.* Technical Disease Card.
- [29] OIE, 2014. "Lumpy skin disease technical disease."
- [30] Kitching, R. P., 2003. "Vaccines for lumpy skin disease, sheep pox and goat pox." *Developments in Biological*, vol. 114, pp. 161-167.
- [31] Tulman, E. R., Afonso, C. L., Lu, Z., Zsak, L., Sur, J. H., Sandybaev, N. T., Kerembekova, U. Z., Zaitsev, V. L., Kutish, G. F., *et al.*, 2002. "The genomes of sheeppox and goatpox viruses." *Journal of Virology*, vol. 76, pp. 6054-6061.
- [32] Le Goff, C., Lamien, C. E., Fakhfakh, E., Chadeyras, A., Aba-Adulugba, E., Libeau, G., Tuppurainen, E., Wallace, D. B., Adam, T., *et al.*, 2009. "Capripoxvirus G-protein-coupled chemokine receptor: a host-range gene suitable for virus animal origin discrimination." *Journal of General Virology*, vol. 90, pp. 1967-1977.
- [33] Lamien, C. E., Le, G. C., Silber, R., Wallace, D. B., Gulyaz, V., Tuppurainen, E., Madani, H., Caufour, P., Adam, T., *et al.*, 2011a. "Use of the Capripoxvirus homologue of Vaccinia virus 30 kDa RNA polymerase subunit (RPO30) gene as a novel diagnostic and genotyping target: development of a classical PCR method to differentiate Goat poxvirus from Sheep poxvirus." *Veterinary Microbiology*, vol. 149, pp. 30-39.
- [34] Lamien, C. E., Lelenta, M., Goger, W., Silber, R., Tuppurainen, E., Matijevic, M., Luckins, A. G., and Diallo, A., 2011b. "Real time PCR method for simultaneous detection, quantitation and differentiation of capripoxviruses." *Journal of Virological Methods*, vol. 171, pp. 134-140.
- [35] Mebratu, G. Y., Kassa, B., Fikre, Y., and Berhanu, B., 1984. "Observation on the outbreak of lumpy skin disease in Ethiopia." *Review Elev. Medical Veterinary Pays Tropics*, vol. 37, pp. 395–399.
- [36] Tuppurainen and Oura, C. A., 2011. "Review: Lumpy skin disease: An emerging threat to europe, the middle east and asia." *Journal of Transboundary and Emerging Diseases*, vol. 59, pp. 40-48.
- [37] Bhanuprakash, V., Venkatesan, G., Balamurugan, V., Hosmani, M., Yogisharadhya, R., Chauhan, R. S., Pande, A., Mondal, B., and Singh, R. K., 2010. "Pox outbreaks in sheep and goats at makhdoom (uttar pradesh), india: Evidence of sheeppox virus infection in goats." *Transboundary and Emerging Diseases*, pp. 375-382.
- [38] Tuppurainen, S., Pearsson, C. R., Bankowska, B. K., Knowles, N. K., Amareen, S., Frost, L., Henstock, M. R., Diallo, A., and Martens, P. P., 2014. "Characterization of sheep pox virus vaccine for cattle against lumpy skin disease virus." *Antiviral Research*, vol. 109, pp. 1-6.
- [39] Bhanuprakash, V., Hosamani, M., and Singh, R. K., 2011. "Prospects of control and eradication of capripox from the Indian subcontinent: A perspective." *Antiviral Research*, vol. 91, pp. 225-232.
- [40] Tuppurainen, Venter, E. H., Shisler, J. L., Gari, G., Mekonnen, G. A., Juleff, N., Lyons, N. A., De Clercq, K., Bouden, T. R., *et al.*, 2015. "Review: Capri poxvirus diseases: Current status and opportunities for control." *Transboundary and Emerging Diseases*, vol. 64, pp. 729-745.
- [41] CFSPH, 2008. *The center for food security and public health.* Iowa State University: College of Veterinary Medicine And Institution of International Cooperation in Cattle Biologics, An Oie Collaborating Center.
- [42] Tuppurainen, Venter, E., and Coetzer, J., 2005. "The detection of lumpy skin disease virus in samples of experimentally infected cattle using different diagnostic techniques." *On derstepoort Journal of Veterinary Research*, vol. 72, pp. 153–164.
- [43] Getachew, G., Waret-Szkuta, A., Grosbois, V., and Jacquite, P., 2010. "Risk Factors Associated with observed clinical lumpy skin disease in Ethiopia." pp. 68-84.

- [44] Alaa, A., Hatem, M., and Khaled, A., 2008. "Polymerase chain reaction for rapid diagnosis of a recent lumpy skin disease virus incursion to Egypt." *J. Arab Biotech*, vol. 11, pp. 293-302.
- [45] Vorster, H. and Mapham, H., 2008. "Pathology of lumpy skin disease." *Livestock Health and Production Review*, vol. 1, pp. 16-21.
- [46] Radostits, Gay, C., Hinchcliff, W., and Constable, D., 2006. *Veterinary medicine A text book of the diseases of cattle, horses, sheep, pigs and goats*. 10th ed. Philadelphia, USA: WB Saunders Co., pp. 1424- 1426.
- [47] Gari, G., Bonnet, P., Roger, F., and Waret-Szkuta, A., 2011. "Epidemiological aspects and financial impact of lumpy skin disease in Ethiopia." *Preventive Veterinary Medicine*, vol. 102, pp. 274-283.
- [48] AUSVETPLAN, 2009. "Australian veterinary emergency plan, disease strategy." *Lumpy Skin Disease*,
- [49] Bagla, P. V., 2005. *The demonstration of the lumpy skin disease virus in semen of the experimentally infected bulls using different diagnostic techniques*. MSc thesis.
- [50] Merck Veterinary Manual, 2011. "Integumentary system: Pox diseases: Lumpy skin disease, economic impact of lumpy skin disease."
- [51] Wainwright, S., El Idrissi, A., Mattioli, R., Tibbo, M., Njeumi, F., and Raizman, E., 2013. "Emergence of lumpy skin disease in the Eastern Mediterranean Basin countries." *FAO Empres Watch*, vol. 29, pp. 1-6.
- [52] Babiuk, S., Bowden, T., Parkyn, G., Dalma, B., Manning, L., Neufeld, J., Embury-Hyatt, C., Copps, J., and Boyle, D., 2008b. "Quantification of Lumpy skin disease virus following experimental infection in cattle." *Trans. and Emer. Dis.*, vol. 55, pp. 299-307.
- [53] Haegemana, A., Leeuwa, I. D., Mostin, L., Campe, W. V., Aerts, L., Vastag, M., and Clercq, K. D., 2020. "An Immunoperoxidase Monolayer Assay (IPMA) for the detection of lumpy skin disease antibodies " *Jour. of Vir. Meth.*, vol. 277, p. 113800.
- [54] Brenner, J., Haimovitz, M., Oron, E., Stram, Y., Fridgut, O., Bumbarov, V., Kuznetzova, L., Oved, Z., Aserman, A. W., *et al.*, 2006. "Lumpy skin disease in a large dairy herd in Israel." *Isr. J. Vet. Med.*, vol. 61, pp. 73-77.
- [55] Zhou, J. S., Ma, H. L., and Guo, Q. S., 2004. "Culturing of ovine testicular cells and observation of pathological changes of the cell inoculated with attenuated sheep pox virus." *Chinese Journal Veterinary Science and Technology*, vol. 34, pp. 71-74.
- [56] Binopal, Y. S., Ongadi, F. A., and Chepkwony, J. C., 2001. "Alternative cell lines for the propagation of lumpy skin disease virus." *Journal of Veterinary Research*, vol. 68, pp. 151-153.
- [57] Babiuk, S., Parkyn, G., Copps, J., Larence, J. E., Sabara, M. I., Bowden, T. R., Boyle, D. B., and Kitching, R. P., 2007. "Evaluation of an ovine testis cell line (OA3.Ts) for propagation of capripoxvirus isolates and development of an immunostaining technique for viral plaque visualization." *Journal of Veterinary Diagnostic Investigation*, vol. 19, pp. 486-491.
- [58] Bowden, T. R., Coupar, B. E., Babiuk, S. L., White, J. R., Boyda, V., Ducha, C. J., Shiell, B. J., Uedad, N., Parkynb, G. R., *et al.*, 2009. "Detection of antibodies specific for sheeppox and goatpox viruses using recombinant capripoxvirus antigens in an indirect enzyme-linked immunosorbent assay." *J. Virol Methods*, vol. 161, pp. 19-29.
- [59] Murray, L., Edwards, L., Tuppurainen, E. S. M., Bachanek-Bankowska, K., Oura, C. A. L., Mioulet, V., and King, D. P., 2013. "Detection of capripox virus DNA using a novel loop-mediated isothermal amplification assay." *BMC Vet. Res.*, vol. 9, p. 90.
- [60] Lefèvre, P. C. and Gourreau, J. M., 2010. *Lumpy skin disease. In: Lafèvre, p.C., blancou, j., chermette, r., uilenberg, g. (eds.), infectious and parasitic diseases of livestock*. Lavoisier, Paris, pp. 393-407.
- [61] Abera, Z., Degefu, H., Gari, G., and Kidane, M., 2015. "Sero-prevalence of lumpy skin disease in selected districts of west Wollega zone." *BMC Vet Res.*, vol. 11, pp. 1-9.
- [62] Haegeman, A., Zro, K., Sammin, D., Vandenbussche, F., Ennaji, M., and De Clercq, K., 2016. "Investigation of a possible link between vaccination and the 2010 sheep pox epizootic in Morocco." *Trans Emerg Dis.*, vol. 63, pp. e278-87.
- [63] Gari, G., Grosbois, V., Waret-Szkuta, A., Babiuk, S., Jacquiet, P., and Roger, F., 2012. "Lumpy skin disease in Ethiopia: Seroprevalence study across different agro-climate zones." *Acta Trop.*, vol. 123, pp. 101- 106.
- [64] Tuppurainen, Alexandrov, T., and Beltrán-Alcrudo, D., 2017b. *Lumpy skin disease field manual –A manual for veterinarians*. Rome: FAO Cattle Production and Health Manual No. 20. pp. 3-6.
- [65] Ochwo, S., VanderWaal, K., Munsey, A., Nkamwesiga, J., Ndekezi, C., and Mwiine, F., 2019. "Sero-prevalence and risk factors for lumpy skin disease virus sero-positivity in cattle in Uganda " *BMC Vet. Resear* vol. 15, p. 236.
- [66] Direksin, K., Joo, H., and Goyal, S. M., 2002. "An immunoperoxidase monolayer assay for the detection of antibodies against swine influenza virus." *J. Vet. Diagn. Invest.*, vol. 14, pp. 169-171.
- [67] Liang, Wang, H., Zhang, L., Gu, H., and Zhang, G., 2014. "Development of a novel immune-peroxidase monolayer assay for detection of swine Hepatitis E virus antibodies based on stable cell lines expressing the ORF3 protein." *Acta Vet. Hung.*, vol. 62, pp. 243-256.
- [68] Pileri, E. M., Cortey, F., Rodríguez, M., Sibila, L., Fraile, D., and Segalés, J., 2014. "Comparison of the immunoperoxidase monolayer assay and three commercial ELISAs for detection of antibodies against porcine circovirus type 2." *Vet. J.*, vol. 201, pp. 429-432.
- [69] Afayoa, M., Atuhaire, D. K., Ochwo, S., Okuni, J. B., Majid, K., Mwiine, F. N., Olaho-Mukani, W., and Jok, L. O., 2014. "Comparison of immunoperoxidase monolayer assay, polymerase chain reaction and

- haemadsorption tests in the detection of African swine fever virus in cell cultures using Ugandan isolates." *J. Gen. Mol. Virol.*, vol. 6, pp. 36–45.
- [70] Coetzer, J. A. W., Tuppurainen, E., Babiuk, S., and Wallace, D. B., 2018. "Lumpy skin disease." Available: <https://www.researchgate.net/publication/326258692>
- [71] OIE, 2018. *OIE terrestrial manual chapter 3.4.12*. Lumpy Skin Disease, pp. 1158-1171.